

Avian bone pathologies from Arikara sites in South Dakota.—Vertebrate remains recovered in aboriginal sites often provide the archaeologist with valuable data pertaining to the economic and social use of animals by various Indian groups. Certain groups of birds such as the Anatidae comprised a significant part of their diet (Howard, Univ. Calif. Publ. Zool. 32:301-387, 1929; Parmalee, Bull. Ill. Arch. Surv. 10:137-155, 1976) while others, for example representatives of the Accipitridae and Corvidae, played a major role in ceremonial and related customs (Ubelaker and Wedel, Am. Antiquity 40: 444-452, 1975). The identification of avian bones found during archaeological excavations may provide the zoologist with noteworthy prehistoric or early historic species' distribution and abundance records. Data pertaining to sex and age ratios of certain species, season of death (collection by the Indian), significant taxonomic characters, and osteological anomalies may also be obtained from archaeologically derived faunal samples.

The occurrence of mammalian bones which exhibit some form of anomaly or pathology are recovered occasionally in Indian refuse deposits, but similar elements of birds are extremely rare. This may be due to the fact that birds were seldom taken in numbers comparable to those of mammals and, consequently, fewer elements were preserved. However, the chances of a bird with a broken leg or especially a wing surviving during the period necessary for healing are probably small. Even if such a break would heal in a manner that would allow the individual to again function normally, the possibility that the Indian would later kill such a bird and its bone be preserved in the midden debris is even more remote. Therefore, the recovery of 3 extreme cases of bird bone pathology encountered during identification and analysis of an avifauna from 51 Arikara sites in South Dakota are worthy of description.

Archaeological salvage work was carried out along the Missouri River in North and South Dakota from about 1950 to 1965 prior to the construction of 5 major dams by the U.S. Army Corps of Engineers. During this period considerable quantities of animal refuse were salvaged from several Plains Indian village sites which were to be inundated. I have examined nearly 3100 bird bones from 51 of these South Dakota sites which were formerly occupied by groups of Arikara. This Plains tribe was originally a part of the Pawnee confederacy; these Indians migrated to the Middle Missouri River area from Nebraska and established numerous villages along the river. Approximately 68 species of birds, representing 22 families, were identified. Remains of waterfowl, hawks and eagles, grouse, and corvids comprised about 84% of the total.

A minimum of approximately 870 individuals were represented in these 51 sites and of this total, elements of only 3 birds, 2 hawks and 1 duck, exhibited a pathological condition. Four such elements, occurring in the same archaeological excavation unit and undoubtedly from the same individual, were recovered at the Crow Creek site (39BF11: occupied ca. AD 1400-1550). The bones consisted of a right tarsometatarsus and radius/ulna and a left humerus (Fig. 1) and were those of a hawk (*Buteo* sp.). Several of the broad-winged hawks are extremely difficult to separate osteologically even when the elements are normal, so these distorted bones make a specific determination more uncertain; however, these compare most closely with the Rough-legged Hawk (*B. lagopus*).

The most interesting of the 4 elements are the radius and ulna which had been broken about $\frac{1}{4}$ the distance from the distal end. During the healing process these bones became fused at or near the point of fracture by a bridge of callus bone. The distal $\frac{1}{3}$ to $\frac{1}{2}$ of these elements was greatly swollen with porous new bone which resembles a tumor. This swollen appearance is apparently due, in part, to the overlapping broken ends of the bone which double the normal diameter of each; healing in such a manner would tend to shorten the length of the wing. The distal articulating surfaces of the radius and ulna

appeared only minimally affected and there was probably little or no disruption in free articular movement with the cuneiform, scapholunar, and proximal end of the carpo-metacarpus. Once complete healing had occurred, the bird was probably able to again fly.

Neither the humerus nor the tarsometatarsus recovered in the same unit with the pathological radius/ulna had been broken, but the deformities and surface irregularities apparent in both suggest they may well have been from the same hawk. It is possible that these 2 elements, as well as others, could have been affected as a result of the traumatic condition of the broken wing and/or possibly inadequate diet during the healing process. The proximal end of the humerus is bent upward (anconal view) and the area of attachment of the latissimus dorsi, pneumatic fossa, bicipital surface, and bicipital furrow appear granular or roughened. The proximal end of the tarsometatarsus is also bent upward (anterior view) and slightly twisted (Fig. 1). Although the break in the wing of this hawk healed completely, the total effect osteologically may have been detrimental to a normal existence.

The second incidence of pathology involved the left tarsometatarsus of a hawk, possibly Rough-legged Hawk or Red-tailed Hawk (*B. jamaicensis*) found at the Black Partizan site (39LM218: occupied ca. AD 1550-1675). The element had been broken near the distal end (Fig. 2, A) and, as evidenced by the deposition of porous new bone, a certain amount of healing had taken place. Whether or not the fracture had completely healed at the time of the bird's death is uncertain since the proximal section of the tarsometatarsus was not recovered. The callus bone was extremely irregular, however, and the use of the tarsometatarsus was probably considerably reduced as evidenced by the thin areas of ossification. In any event, this hawk had survived long enough before being killed to permit a considerable amount of healing at the fracture.

In his study of bone injuries in birds, Tiemeier (Auk 58:350-359, 1941) found that nearly 13% of 256 skeletons of the ducks he examined possessed one or more broken or otherwise damaged and repaired elements. Generally, for all groups of birds he examined, wing and leg elements were the ones most subject to injury, although damage to skulls, sterna, and furcula, especially in the passerines, was not uncommon. Of 6212 bird skeletons (59 families) examined by Tiemeier (op. cit.) from the collections of the Museum of Natural History, University of Kansas, Lawrence, no injury to the coracoid was mentioned. Therefore, the apparent rarity of injury to this element, coupled with the extreme pathological condition of a left coracoid from the Hosterman site (39P07: occupied ca. AD 1550-1675) is of particular interest.

This duck coracoid (Fig. 2, B-D) appears to have been broken or at least severely damaged in the area of the glenoid and/or scapular facets. Unlike the hawk elements described above, the callus was small and very compact, although the bone exhibited an extreme degree of deformity. The shaft was divided into 2 sections, producing 1 large and 1 small hole (viewed laterally) between them; the scapular facet appears as a deep U-shaped groove; the glenoid facet is reduced, or divided, and bent at about a 45° angle; and the surface of the ventral "half" of the shaft possesses an oblong depression in which the head of the humerus may have articulated. Because of its deformed condition, this element could not be specifically identified; the overall length and general configuration of the head and sternal facet compare with that of the Mallard (*Anas platyrhynchos*). There is little doubt that such an injury to the coracoid would have inhibited the wing from functioning normally and would have limited or entirely prohibited its use for flight until healed.

At least 1 tribe of Plains Indians, the Mandan of North Dakota, are known to have kept live owls as soothsayers (Thwaites, ed., Early Western Travels, Vol. 23, Arthur H. Clark

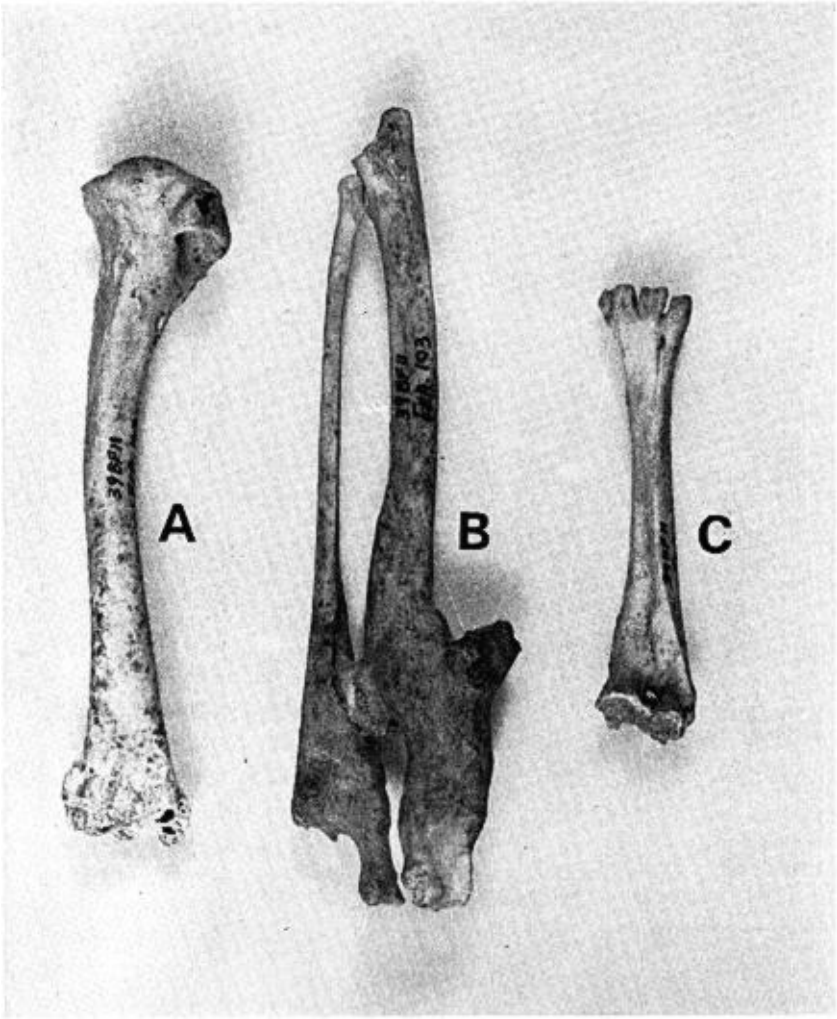


FIG. 1. Pathological conditions of hawk (*Buteo* sp.) elements from the Crow Creek site, South Dakota. A: left humerus, anconal view; B: fused right radius and ulna, palmar view; C: tarsometatarsus, anterior view.

Co., Cleveland, OH, 1906), but there is no evidence suggesting that hawks were kept alive for any reason. In discussing animal ceremonialism of the Miwok Indians of California, however, Heizer and Hewes (*Am. Anthropologist* 42:587-603, 1940) state that "Eagles, condors and falcons were kept captive, and might be traded from tribe to tribe," but apparently such birds were held only temporarily. Eagle trapping was a significant trait of all Plains tribes and a ritual which involved a considerable amount of preparation and

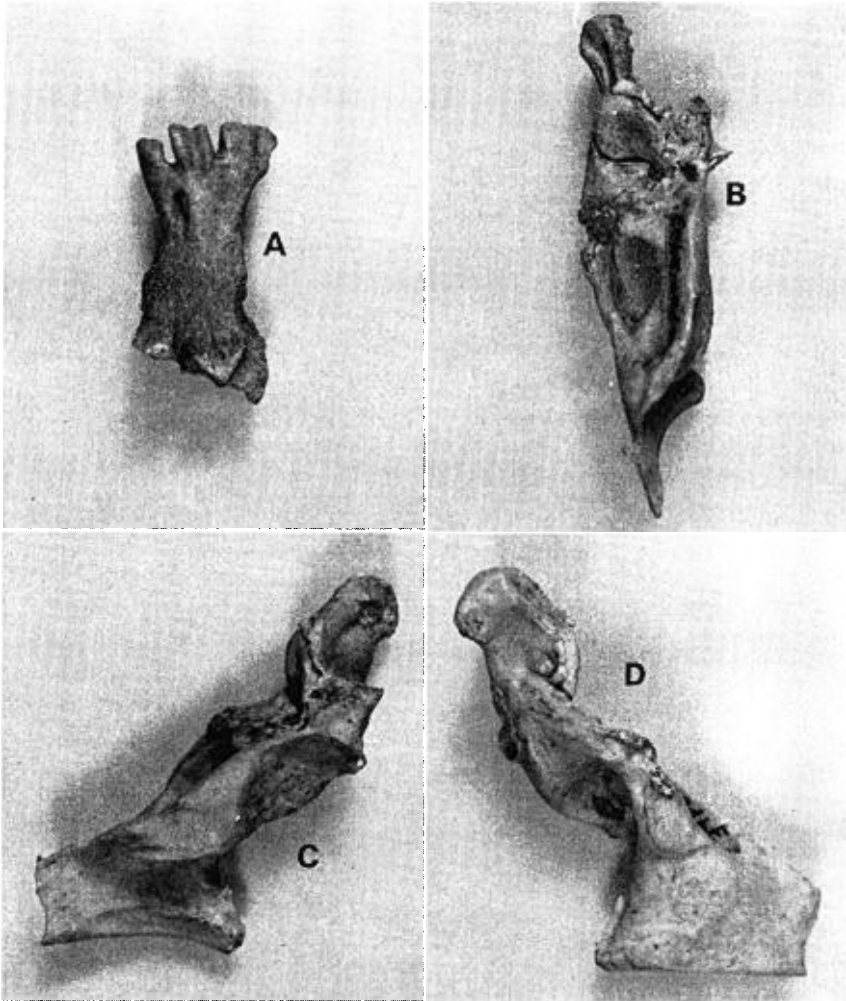


FIG. 2. A: anterior view of a fractured left tarsometatarsus of a hawk (*Buteo* sp.) from the Black Partizan site, South Dakota. Three views (B, lateral; C, dorsal; D, external) of a fractured left duck coracoid from the Hosterman site, South Dakota.

organization (Wilson, *Am. Mus. Nat. Hist. Anthro. Papers* 30:99-245, 1928). Large numbers of hawks and eagles were often taken during these hunts and, although the first few eagles caught were sometimes kept as decoys, most were killed at the end of the hunt. There is no mention of hawks being used in a like manner. Hargrave (*Univ. Ariz. Anthro. Papers* No. 20:1-67, 1970), in his osteological study of macaws (*Ara* spp.) from prehistoric Pueblo sites in Arizona and New Mexico, found that 47% of the 145 individuals exam-

ined displayed pathological bones; he concluded these conditions reflected normal accidents or dietary deficiencies.

The high percentage of bone pathologies evident in the macaws are indicative of a captive state with inadequate diet and generally poor treatment contributing to this condition. With no evidence of the Plains Indian keeping captive hawks, it may be reasonably assumed that the 2 birds exhibiting fractured bones were injured in "natural" accidents. Regardless of the cause, the fact remains that many wild birds which suffer severe fractures are able to survive adverse conditions during the healing period and eventually return to their natural mode of life. The broken and repaired humeri of ducks described and illustrated by Abbott (Auk 60:447, 1943) and Dillon (Auk 78:273-274, 1951) exemplify the fact that a healed break of a major wing element, even though distorted, may enable the bird to regain the power of flight. The extremely deformed coracoid from the Hosterman site is of special interest, however, both from the standpoint of how such an injury occurred and its possible effect on normal wing movement.—PAUL W. PARMALEE, *Dept. of Anthropology, Univ. of Tennessee, Knoxville 37916. Accepted 1 Nov. 1976.*

Nest reciprocity in Eastern Phoebes and Barn Swallows.—A few investigations of the Eastern Phoebe (*Sayornis phoebe*) and Barn Swallow (*Hirundo rustica*) have revealed use, with modification, of old nests of 1 species by the other (Stoner, New York State Mus. Circ. 22:1-42, 1939; Graber et al., Ill. Nat. Hist. Surv. Biol. Note No. 86, 1974; Jackson and Weeks, Alabama Birdlife 24:7-9, 1976).

In March 1970 on Crane Naval Ammunition Depot (NAD Crane), Indiana, I examined and marked all Eastern Phoebe and Barn Swallow nests that remained under bridges and culverts from previous nesting seasons. Of the 242 old nests examined, I found 7 instances of reciprocal use—3 former Barn Swallow nests modified by phoebes, 1 phoebe nest converted by a Barn Swallow, and 3 nests illustrating multiple reciprocity. In these and subsequent modifications, the pattern was similar, with Barn Swallows adding mud and dried grass, and phoebes adding moss to the nests' rims; each species also lined the nest with the appropriate material.

The multiple reciprocity nests were all found beneath bridges. The largest nest, 32 cm in height, was composed of 7 alternating Barn Swallow and phoebe nests beginning with a Barn Swallow base (Fig. 1). Another nest was of similar construction but composed of 4 tiers of alternating nests built on a phoebe base and 24 cm in height. A third nest appeared to be a single, excessively large (21 cm in height) Barn Swallow nest modified by phoebes, and only at removal at the end of the season did the nest separate to reveal a second, intermediate layer of phoebe nesting material.

Of the 235 normal nests marked prior to the 1970 nesting season, 8 were modified and used during the season by the other species. Six old Barn Swallow nests were adapted by phoebes, and 2 old phoebe nests converted by Barn Swallows. One of these latter nests and another phoebe nest, built early in the 1970 season, fledged broods of phoebes prior to their modification and successful late season use by Barn Swallows.

Since old nests were removed at the end of the 1970 season, no nests were available for reuse in spring 1971. However, 1 phoebe and 1 Barn Swallow nest built early in the 1971 season were subsequently converted and used by the alternate species. All nests