

## RAPTOR REHABILITATION AT THE OKLAHOMA CITY ZOO

by

John C. Snelling  
Oklahoma City Zoo  
Route 1, Box 478  
Oklahoma City,  
Oklahoma 73111

### *Abstract*

A program of raptor rehabilitation has been conducted at the Oklahoma City Zoo in an effort to conserve wildlife, to assist the public, and to gain knowledge about the care and treatment of injured birds. From October 1973 through December 1974 Red-tailed Hawks and Great Horned Owls constituted 45.3 percent of all birds donated. Donations from the public comprised 89.0 percent of the birds treated. Wing injury was found in 52.0 percent; radiographs showed that 22.7 percent of all cases involved gunshot. Binding of the limb with Vetrap<sup>R</sup>, following surgery (where indicated) with ketamine anaesthesia (ca. 33 mg/kg), followed standard medical procedures. While recuperating, birds were kept quiet in small, dark containers, and fed on a whole animal diet. To reduce muscle atrophy and loss of condition, release was attempted as soon as possible. Large high cages, high perches, falconry techniques, and the assistance of local falconers all contributed to preparations for release. The release rate of 39.6 percent compared favorably with figures given for other rehabilitation projects.

There is a discussion of the need for more public education in raptor ecology and more exchange of information among rehabilitators. Techniques—the use of tranquilizers with anesthetics, practice in hunting before release, and banding, for example—are also discussed.

### *Introduction*

The past two decades have been marked by man's increased awareness of his environment and concern for its stability. This "ecological consciousness" is perhaps nowhere better exemplified than in his concern for the well-being of predators, long considered his enemies. Partly because of their unique position as indicators of environmental pollution by pesticides, the birds of prey, often called raptors, have played a major role in the environmental issue.

In 1965 a conference was convened at the University of Wisconsin to discuss the plight of the Peregrine Falcon (*Falco peregrinus*) and other raptorial birds. The proceedings of this meeting (Hickey 1969) are a landmark in the study of raptor populations and ecology. Indeed, the conference served to spark a continuing interest in the study of avian predators. The Raptor Research Foundation, an important compiler and instigator of research on birds of prey, was also formed during the Peregrine Conference.

Although contamination by pesticides (Cade et al. 1971) and habitat destruction (Fisher et al. 1969) are the most serious threats to raptors, direct persecution by man (shooting, nest robbing, etc.) has long been identified as a negative influence on this wildlife resource. Zoos, government wildlife agencies, schools and universities, and private individuals are frequently called upon to care for injured or otherwise supposedly "helpless" birds of prey (Pendleton 1975). This paper describes the program of care and rehabilitation for raptors brought to the Oklahoma City Zoo.

There are several reasons why we are involved in raptor rehabilitation. *First*, raptors should be conserved as a useful part of our biota. As a conservation organization the Zoo should make every effort to do what it can to assist *all* wildlife, not just the specimens in captivity. And although most of the individuals we attempt to rehabilitate are not rare or endangered species, such threatened birds may well need our attention in the future. *Second*, by engaging in rehabilitation we are serving the people of Oklahoma who are genuinely concerned about wildlife. The vast majority (89 percent) of raptors donated to the Zoo are brought in by members of the public who have happened upon them by accident and are not familiar with proper care and treatment. In this regard, the Zoo is fulfilling its educational and service role. *Third*, by treating common wild birds for fractures and other illnesses, Zoo personnel gain valuable knowledge about the handling of similar injuries in rarer, exotic specimens within the collection or as brought to us for rehabilitation to the wild.

### *Methods*

Most people call the Zoo prior to bringing a bird to us. In some cases where it is clear that a newly fledged brancher has been found, we make every effort to have the bird returned to its nest area where most often the adults will continue to feed it during the normal developmental process.

When a bird reaches the Zoo, the donor is asked to fill out an entry slip giving basic information—species, age, sex, when and where captured, and most important, the donor's signature releasing all rights to the specimen. Since migratory birds are now protected by federal law, this release would be a mere formality except that it protects the Zoo should a person return later asking for the bird or wanting to know why it is not on display. The donor is told that the Zoo will not necessarily retain the bird but will make every effort to return it to the wild and see that it is cared for humanely in the meantime.

Our policy is to examine each raptor as quickly as possible. If the prognosis for recovery and release is not good—for example, in severe, old, open fractures—we euthanize the bird immediately with an intravenous or intraperitoneal overdose of pentobarbital unless one of the following criteria is met: (1) the bird is a member of an endangered species, (2) the bird's treatment would be a useful learning experience for the Zoo, (3) there exists a specific need for the bird, such as for captive propagation, education, or exhibit purposes. In connection with the last criterion we make every effort to consult local law enforcement personnel of the U.S. Fish and Wildlife Service and Oklahoma Department of Wildlife Conservation.

The first step in treatment of a raptor is to identify it and to determine the nature of its injuries. Uninjured birds or those that are temporarily stunned can be banded with a U.S. Fish and Wildlife Service band and released immediately. Where a branching eyas, or young bird removed from the nest, is involved, the hacking procedure employed by falconers is used (Michell 1959). A hack box or artificial nest is constructed to protect the young and to form a base on which food is supplied daily. In the normal fledging process, the eyas gains flight experience and later independence from the human food source (figure 1). The problem with hacking raptors in the Zoo environment is the potential for predation on resident animals. With large hawks and owls (i.e., Red-tailed Hawk [*Buteo jamaicensis*] and Great Horned Owl [*Bubo virginianus*]), a hack location away from the Zoo and from large numbers of people is selected. We have successfully hacked the insect- and rodent-eating Mississippi Kite (*Ictinia mississippiensis*) and Barred Owl (*Strix varia*) on the Zoo grounds, however. If a bird is injured, a radiograph is made to determine the nature and extent of fractures, if any, and to determine whether gunshot is involved (figure 2). Radiography without chemical or human restraint is quite feasible if the bird is hooded (Stockinette,

Curity<sup>®</sup>, Kendall Orthopedic Products, is suitable), and heavy objects (lead-lined x-ray gloves work well are used to pin the wings or legs out in an appropriate position (figure 3). At this time up to two milliliters of blood are taken from the brachial vein for a study at Oklahoma State University (Stillwater) on avian blood parasites (A. Kocan pers. comm.).

Injured birds with no fractures can best be placed in a darkened box (animal shipping crates work well; some have used cardboard containers) until they recover. Where fractures are involved, the affected limb should be immobilized immediately; we use Bandaging Tape (Vetrap<sup>®</sup>, 3M Animal Care Products) with great success as it does not adhere to feathers (see Fuller in press). For many wing fractures binding is sufficient to effect healing in several weeks. The bird is kept on a good quality diet of whole animals (chicks, chicken necks, rats, and pigeons are our usual food), and remains quiet in the darkened chamber. In cases of severe malnutrition, intubation may be indicated. A blended soup of flat coke, egg yolk, and skinned whole animals (mice, chicks, quail, sparrows) is administered into the crop or stomach with a syringe and rubber catheter (Snelling 1970). For a two-kilogram bird, 15 to 20 ml of fluid should be given several times each day. Intubation can be very effective in saving birds which cannot or will not eat.

In cases of severe fracture, surgery may be indicated. We utilize Ketaset<sup>®</sup> (ketamine hydrochloride, Bristol Laboratories), in an initial intravenous or intramuscular dose of 33 mg/kg of body weight (see also Fuller et al. 1974); one part acepromazine (Ayerst Laboratories) per ten parts Ketaset<sup>®</sup> helps to reduce the convulsions associated with recovery. Standard intramedullary pinning procedures are followed (Mutchler 1972; Redig 1976 Secord 1958), the limb being bandaged with Vetrap<sup>®</sup> following surgery. Pin removal is usually undertaken in two to three weeks, depending on a radiographic determination of bone callous formation.

In order to facilitate successful rehabilitation, we strive to release raptors as soon as possible, a practice which minimizes loss of muscle tone. A critically important step, however, is determining whether the bird can fly well enough to survive. We have followed several different procedures, depending on the individual case.

First, a healed bird—if already experienced in hunting—may simply be banded and released. If it can fly well enough to elude recapture, it is probably well enough to survive. In one case a Red-tailed Hawk that apparently could not fly well was left in a field. Three days later it was relocated, flying perfectly.

Our birds are often transferred from small dark boxes to larger (2x2x3m) cages (figure 4) soon after they are eating properly. This second method utilizes the height of these cages which makes upward flight to a perch possible, allowing evaluation of the bird's strength.

A third approach toward flight evaluation and conditioning is to employ a high perch (called a "Presley" perch) utilized by falconers (Fritz 1974). The bird is fitted with jesses and leash (twice the length its perch is high), and is tied to a perch several meters high. When it is capable of gaining this perch easily, it is deemed releasable. Dr. John Lee (pers. comm.) in Idaho uses this method successfully.

The fourth method is to allow a falconer to exercise and condition the bird; we employed this technique with a Cooper's Hawk (*Accipiter cooperi*) which later was released.

The fifth method, and probably the most reliable one, is to loose each bird in a large flight room for several weeks prior to release; an old barn loft makes an excellent prerelease chamber; here at the Zoo we have used a metal shed 10x5x3m.

During the entire time a bird remains at the Zoo, from entry until final disposition, records are kept on standardized Zoo data forms; these include clinical diagnosis, diet, behavior, treatment, and other potentially useful information. The U.S.F.W.S. Law Enforcement office in Albuquerque, New Mexico, has requested that we keep entry and removal records, but does not require a Special Purpose Permit for rehabilitation as the Zoo is a public institution.

Carcasses of birds that die or are euthanized are sent to museums on request or are turned over to the U.S.F.W.S. for final disposition.

### *Results*

This report covers the period October 1973-December 1974. Fifty-eight raptors (orders Falconiformes and Strigiformes) were donated during the period. Table 1 presents age, sex, and numerical data on the species we have treated; the predominant species are the Red-tailed Hawk, Great Horned Owl and Barred Owl. Of those individuals accurately identified 69.7 percent were immature, and 30.3 percent adult, with 58.3 percent female and 41.7 percent male. Private citizens donated 89.0 percent of our birds; the remaining 11.0 percent came from U.S.F.W.S. law enforcement personnel and the Oklahoma City Animal Welfare Division.

Figure 5 shows that more than half (62.0 percent) of our birds were brought in during the months between September and February—a time when hunters are afield and are most likely to encounter injured birds. It is also the period when northern migrant raptors winter in Oklahoma in large numbers.

Table 2 summarizes the state of injury of raptors donated to the Zoo. No injury could be found for 21.1 percent of the birds. Only 22.7 percent were definitely shot as determined by radiograph analysis, with more Falconiformes than Strigiformes suffering this fate. The 38.0 percent listed as unknown results from our initial reluctance to radiograph all raptors; judging from the experience of others, most of these unknown cases were also probably shot (see Discussion). Wing injuries were more frequent than all other clinical signs, comprising 52.0 percent of all cases treated. The humerus is most likely to be affected; 42.0 percent of all wing injuries involved fractured humeri.

The success of our rehabilitation effort is measured in table 3. Birds which did not survive, because of either spontaneous death or euthanasia, comprised 34.0 percent of our sample. A small number (9.4 percent) of birds were retained for specific uses, and 17.0 percent of the cases were still being treated at the end of December. Most significant for measuring success was the number of rehabilitated birds released to the wild, in our program 39.6 percent; 91.0 percent of these birds were banded.

### *Discussion*

How do these results compare with those of other raptor rehabilitation projects? Most of the published information on raptor rehabilitation to date has come from a small sample of such projects. The University of Minnesota group (Fuller et al. 1974) treated ninety birds of seventeen species over a fourteen-month period. Gunshot accounted for injury to 51 percent of their birds, and 40 percent were released to the wild. These figures are comparable with ours. Perhaps their most noteworthy case was that of an adult Bald Eagle (*Haliaeetus leucocephalus*) treated and released, which was later found breeding in the wild (M. Fuller pers. comm.). Wisecarver and Bogue (1974) also present data with which our effort can be compared. Of 365 birds treated over a seven-year period, 81 percent came from public donation. Only 8 percent were shot, and 47 percent were released to the wild. Aside from

the surprisingly low percentage of birds shot, these figures compare very well with ours. Mutchler (1972, 1973), working with the Hawk Mountain Sanctuary Association, treated over fifty raptors in 1972. Both Mutchler (1972) and Redig (1976) present good information on intramedullary pinning and postoperative care.

Rehabilitation is being undertaken elsewhere, but no success figures are published (T. Buchanan, J. Lee, R. Thacker pers. comm., Maxwell 1972; Spivey 1973).

Several specific points merit discussion. First of all, a massive public education program on the growth and development of young birds (and mammals?) is needed to control needless removal of fledglings from the wild. Each spring we handle several dozen calls per week about "helpless" birds found by the public; the 20.8 percent of our raptors donated without injuries speaks for itself. Media coverage each spring concerning this problem can help. When speaking before school and other groups, we should not fail to mention how young birds achieve self-sufficiency.

With respect to veterinary considerations in treatment, our use of ketamine hydrochloride has proven effective, although the phase of recovery from anesthesia, wherein the birds thrash around quite violently, appears to be a potential danger. We have used Stockinette to restrain a bird during this period. Dr. Pat Redig (pers. comm.) recommends using 1.0 mg/kg diazepam (Valium<sup>R</sup>, Roche Laboratories) in the ketamine dose to reduce the violence of recovery; acepromazine (see Methods) also helps.

We have also seen arthrosis or ankylosis in the wing joints of birds following routine pinning, or taping. P. Redig (pers. comm.) reduces these problems by unbandaging a wing as soon as possible after pinning and using passive physical therapy to exercise joints.

The post mortem finding of herpesvirus in a Great Horned Owl is significant and points to the necessity for adequate isolation of a raptor rehabilitation program from other bird collections. Herpes is a highly virulent virus and has the potential to wipe out a collection of birds (Graham et al. 1975). Another interesting finding, stemming from the cooperative blood data project, is that several of our birds have had *Leucocytozoon* spp. infections sufficient to cause death in young waterfowl (A. Kocan pers. comm.). Both these findings suggest the great potential of raptor rehabilitation projects for generating data other than that strictly on treatment and release of birds.

Future study of rehabilitation might include the technique of practice hunting prior to release. Wisecarver and Bogue (1974) refer to giving eyes or fledgling raptors experience in killing live prey prior to release, as training for successful hunting. Spivey (1973) even presents photographs of this activity. Although we have not used this technique, we can see nothing wrong with it as long as it is low key and away from misinterpretation by the public. Two independent holders of U.S.F.W.S. special "hospital" permits have described to me their practice of using live kill on all birds under their care. While this may restore human confidence in the ability of their birds to kill, we assume that any bird which has lived in the wild for several months already knows how to capture prey. Furthermore killing prey, usually rats in cages, is not the same as hunting in the wild. The Philadelphia Zoo recently lost an irreplaceable egg-laying Monkey-eating Eagle (*Pithecophaga jefferyi*), when she apparently tried to capture a live rabbit; breaking a talon, she bled to death (G. Griswold pers. comm.). Although this tragedy is unusual, it illustrates potential problems with killing in cages.

In the literature, very little mention is made of banding rehabilitated raptors prior to release. Although returns are meager in nearly all bird-banding efforts, there is no other way, short of radio telemetry, to determine what happens to birds once they are released. We have had one return to date, a Red-tailed Hawk found three weeks after release about five kilometers from the release site. Although it was found alive, it had rebroken a fractured leg. Acquisition of a federal bird-banding permit is not recommended for incidental banding, but there is usually a permit holder in the area who will be willing to band rehabilitated birds or make the rehabilitator a subpermittee; some state and federal wildlife personnel could also be of help.

Rehabilitation of birds of prey is a rewarding, worthwhile endeavor. What we need now is more communication among projects so that maximum benefit can be gained from our combined experience. The Rehabilitation Committee of the Raptor Research Foundation is in a unique position to spearhead this effort by providing a forum for all interested parties in its Information Exchange.

At the local level more zoos, universities, state game farms, and private individuals including falconers, are all involved with rehabilitation. In speaking with law enforcement personnel, to whom many injured birds are first given, we found that some are not aware of the various places where birds can be sent for care. At the very least, people in a particular area should be enough in contact so that they are taking the same kinds of data; in this way standardized regional reports may be prepared for each year's activities. Or, perhaps the various rehabilitators in an area could meet to decide who is best equipped to handle certain kinds of birds. For example, a person living far out in the country would be in the best position to hack fledgling raptors. And falconers are often best equipped to rehabilitate birds that need extensive exercise prior to release.

We should also be weighing the kind of question raised by Smith (1974) about "limiting the volume of rehabilitation on common species." Given limited resources, greater effort in saving a few threatened, rare, or endangered species may be more appropriate than effort spent on a wide variety of more common species—*after* the basics have been learned on common species.

### *Acknowledgements*

Many people have aided in the success of this project. Drs. Wesley Johnson and Alma Lee Perotka examined birds, made radiographs, and performed surgery, often on their own time. Members of the Zoo's bird staff assisted in feeding, and a volunteer, Mr. Bryan Gardner, was helpful in all aspects of the project. The administration of the Oklahoma City Zoo, especially its Director, Mr. Lawrence Curtis, is to be commended for financing and encouraging a project separate from the normal display of animals. Drs. Bedford Vestal and Pat Redig and Messrs. Mark Fuller and Roger Thacker read and made helpful suggestions on drafts of the manuscript. Ms. Mary Wilson assumed the task of typing all drafts and the final manuscript.

Lastly, I thank the citizens of Oklahoma who through their thoughtfulness in bringing injured birds to our attention, assist greatly in the conservation of our raptor resource.

*Literature Cited*

- Cade, T. J., J. L. Lincer, C. M. White, D. G. Roseneau, and L. G. Swartz. 1971. DDE residues and eggshell changes in Alaskan falcons and hawks. *Science* 172(3986):955-957.
- Fisher, J., N. Simon, and J. Vincent. 1969. *Wildlife in danger*. New York: Viking Press. 368 pp.
- Fritz, B. J. 1974. The Presley perch. *Hawk Chalk* 13(1):44-46.
- Fuller, M. R., P. T. Redig, and G. E. Duke. 1974. Raptor rehabilitation and conservation in Minnesota. *Raptor Research* 8(1/2):11-19.
- Fuller, M. R. 1975. A technique for holding and handling raptors. *J. Wildl. Manage.*, in press.
- Graham, D. L., C. J. Mare, F. P. Ward, and M. C. Peckham. 1975. Inclusion body disease (herpesvirus infection) of falcons. *J. Wildl. Diseases* 11(1):83-91.
- Hickey, J. J., ed. 1969. *Peregrine falcon populations, their biology and decline*. Madison: University of Wisconsin Press. 596 pp.
- Maxwell, P. D. 1972. Notes on the bird of prey project at San Francisco Zoological Gardens. Proc. 48th Annual American Assoc. Zool. Parks and Aquariums Conference, Portland, Oregon pp. 3-18.
- Michell, E. B. 1959. *The art and practice of hawking*. Boston: Charles T. Branford Co. 291 pp.
- Mutchler, T. M. 1972. Surgical treatment by pinning of longbone fractures on raptors. Hawk Mountain Sanctuary Assoc. Newsletter 44:39-50.
- Mutchler, T. M. 1973. Notes on the care of sick and injured birds. Hawk Mountain Sanctuary Assoc. Newsletter 45.
- Pendleton, D. 1975. Bird doctors: fight for flight. *Science News* 107:106-107.
- Redig, P. T. [1976] Surgical approaches to the long bones of raptors. In C. Schroeder, ed. *Zoo medical book*, sponsored by Morris Animal Found., in press.
- Secord, A. C. 1958. Fractures in birds repaired with the Jonas splint. *Vet. Med.* 53:655-656.
- Smith, John. 1974. Informal discussion. Proceedings of the Conference on Raptor Conservation, Ft. Collins, Colo. *Raptor Research* 8:43.
- Snelling, J. C. 1970. Recovery of a sick Lanner through intubation feeding. *J. N. Amer. Falconers' Assoc.* 9:22-25.
- Spivey, M. 1973. A school opens for hunting birds to learn to live. *Smithsonian* 4(1):33-38.
- Wisecarver, J. and G. Bogue. 1974. Raptor rehabilitation at the Alexander Lindsey Junior Museum. *Raptor Research* 8(1/2):6-10.

**Table 1**  
Raptors Donated to the Oklahoma City Zoo  
October 1973 - December 1974

	Age			Sex			Total
	Adult	Immature	Not Identified	Male	Female	Not Identified	
<b>Falconiformes</b>							
Accipitridae							
<i>Ictinia mississippiensis</i>	0	5	0	0	1	4	5
<i>Circus cyaneus</i>	0	1	0	1	0	0	1
<i>Accipiter cooperi</i>	0	1	0	0	1	0	1
<i>Buteo jamaicensis</i>	6	9	0	4	6	5	15
<i>B. j. harlani</i>	1	1	0	0	0	2	2
<i>Buteo linneatus</i>	0	1	0	1	0	0	1
<i>Buteo swainsoni</i>	1	2	0	1	2	0	3
<i>Buteo lagopus</i>	1	0	0	1	0	0	1
<i>Buteo regalis</i>	0	1	0	1	0	0	1
<i>Aquila chrysaetos</i>	0	1	0	0	0	1	1
<i>Haliaeetus leucocephalus</i>	1	0	0	0	1	0	1
Falconidae							
<i>Falco sparverius</i>	0	0	3	1	2	0	3
Total	10	22	3	10	13	12	35
Percent	28.6	62.9	8.6	28.6	37.1	34.3	
<b>Strigiformes</b>							
Tytonidae							
<i>Tyto alba</i>	0	0	2	0	0	2	2
Strigidae							
<i>Asio otus</i>	0	0	1	0	0	1	1
<i>Strix varia</i>	0	0	5	0	1	4	5
<i>Otus asio</i>	0	0	2	0	0	2	2
<i>Bubo virginianus</i>	0	1	6	0	0	7	7
<i>Speotyto cunicularia</i>	0	0	1	0	0	1	1
Total	0	1	17	0	1	17	18
Percent	0	5.6	94.4	0	5.6	94.4	
Grand Total	10	23	20	10	14	29	53
Percent	18.9	43.4	37.7	18.9	26.4	54.7	



**Table 2**  
Types of Injury to Raptors Donated to the Oklahoma City Zoo  
October 1973 - December 1974

	INJURED												NOT INJURED		
	Shot			Not Shot						Unknown <sup>5</sup>			Falconer's Escape	Nestling	
	Head	Back	Leg	Head	Back	Leg	Wing	Head	Back	Leg	Wing	Stunned			
Falconiformes	2	3	6	1	1	1	1	1	2	5	4	2	1	6	20.0%
	28.6% <sup>4</sup>			14.3%						37.1%					
Strigiformes	1	3		1	1	2	1			1	3	3 <sup>3</sup>		4	22.2%
	16.7%			22.2%						38.9%					
TOTAL	2	4	9	2	2	3	2	1	2	6	7	5	1	10	21.1%
	22.7%			18.3%						38.0%					

<sup>1</sup> humerus    <sup>2</sup> other    <sup>3</sup> one hit by automobile    <sup>4</sup> all percentages adjusted for multiple injuries    <sup>5</sup> not radiographed

**Table 3**  
Disposition of Raptors Donated to the Oklahoma City Zoo  
October 1973 - December 1974

	Did not survive					Retained			Released			Pending	
	Euthanized	Died	M <sup>1</sup>	R <sup>2</sup>	Carcass F <sup>3</sup>	U <sup>4</sup>	State	OKC Zoo	Other Zoo	Research	Hack	Simple Release	Recovery
Falconiformes	6	6	7	2	2	1	1	2		1	7	6	6
			34.3%					8.6%			40.0%		17.1%
Strigiformes	1	5 <sup>5</sup>	1	2	3		1	1			4	3	3
			33.3%					11.1%			38.9%		16.7%
Total	7	11	7	3	4	4	1	3	1	1	11	9	9
			34.0%					9.4%			39.6%		17.0%

<sup>1</sup> museum specimen    <sup>2</sup> research    <sup>3</sup> frozen    <sup>4</sup> unknown    <sup>5</sup> one with herpesvirus diagnosed from liver



Figure 1. A hack box for American Kestrels (*Falco sparverius*) can be made from a cardboard box. This one was placed in the rafters of a shed.

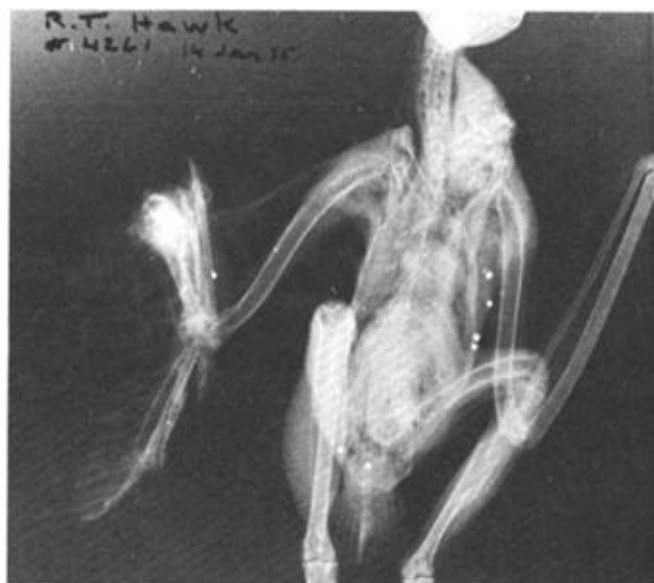

Figure 2. Typical radiograph of a Red-tailed Hawk shows the presence of lead shot and the resultant skeletal damage. Six pellets caused fracture of the left tarso-metatarsus, and extensive destruction of the right radius and ulna.

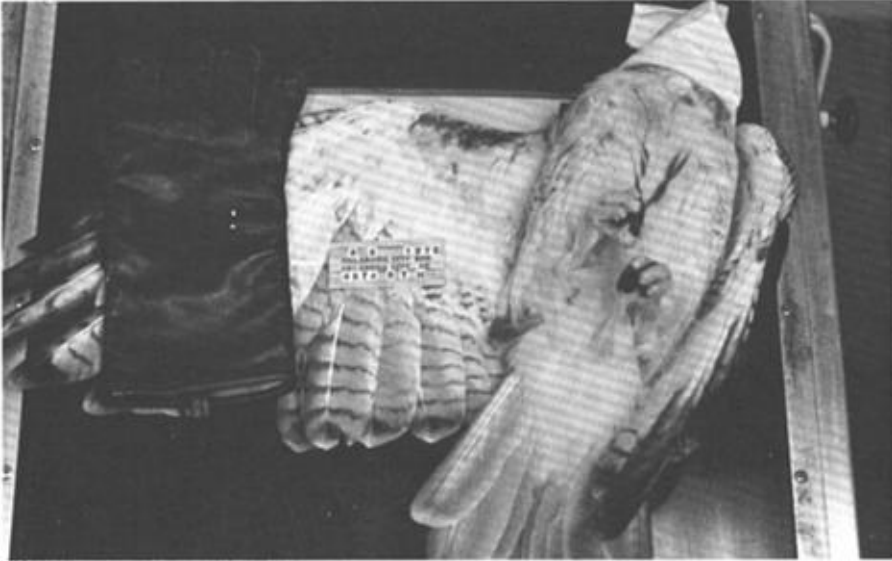


Figure 3. Immobilization of an adult Red-tailed Hawk for radiography. By taking advantage of the immobility response, one can get wild birds to remain still on their backs long enough to make the exposure. A crude hood is used, and a weighted glove keeps the wing extended. Of course, care must be taken when releasing and grasping the legs.



Figure 4. Wire cage, with inner plywood and burlap lining, used to house raptors during recuperation. The two-meter height of these enclosures affords some exercise when a bird jumps to perch near the top.

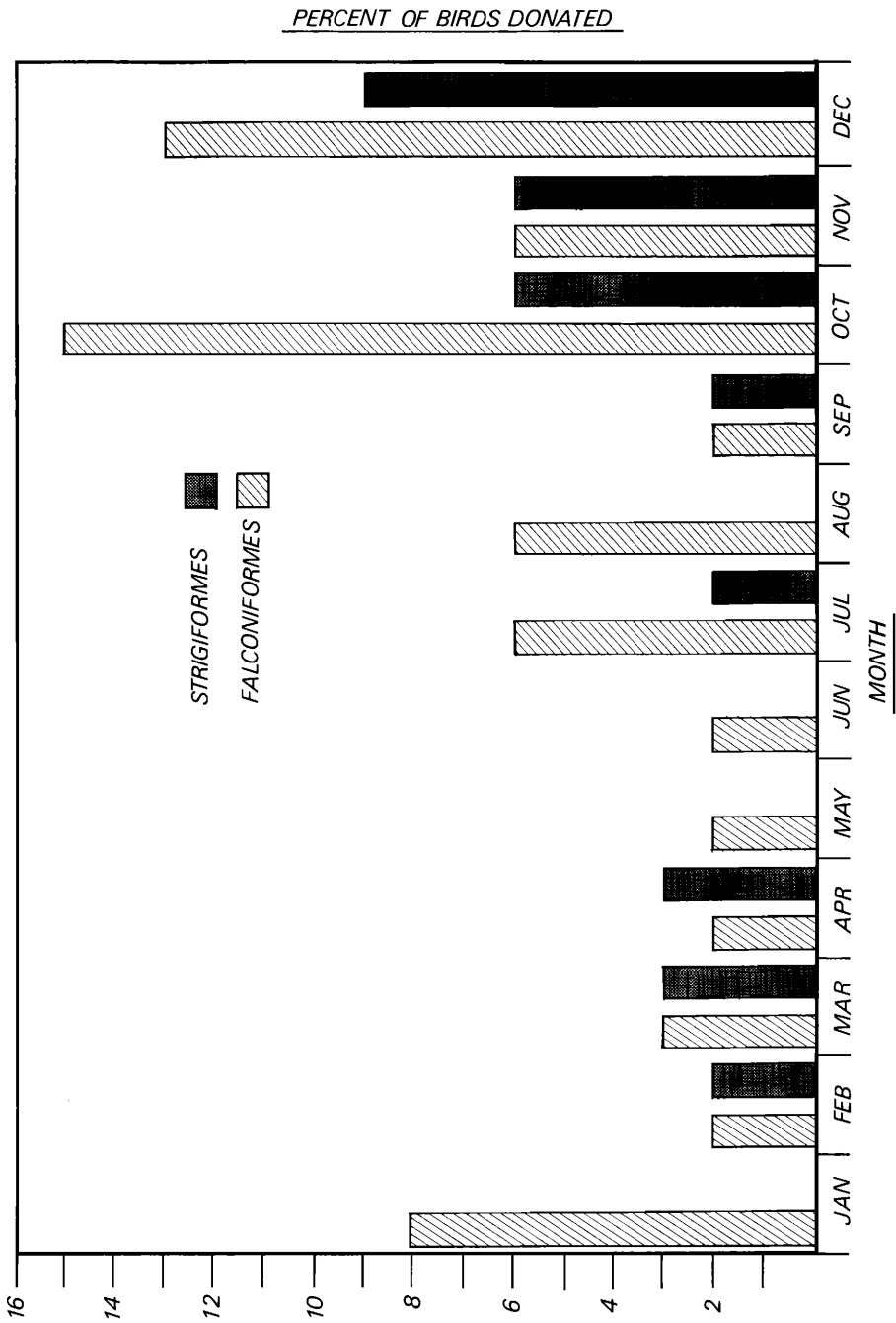


Figure 5. Histogram showing the percent of raptors donated to the Oklahoma City Zoo each month January – December 1974.