

cornfield." About this same time, James Stuart in a journey from Montgomery to Mobile finds the¹ "wild turkey abounds in these (Chattahoochee River) woods, and when fat is an excellent bird: but as the wild turkeys are shot indiscriminately, they are often brought to table when they have not been sufficiently fed. I was always better pleased to see the tame than the wild turkey on the table." Finally, concerning the tame form, Zadock Thompson says in 1842, that² "The Domestic Turkey sprung from this species, and was sent from Mexico to Spain in the 16th century. It was introduced into England in 1524, and into France and other parts of Europe about the same time."

OSTEOLOGY OF THE PASSENGER PIGEON (*ECTOPISTES MIGRATORIUS*).

BY DR. R. W. SHUFELDT.

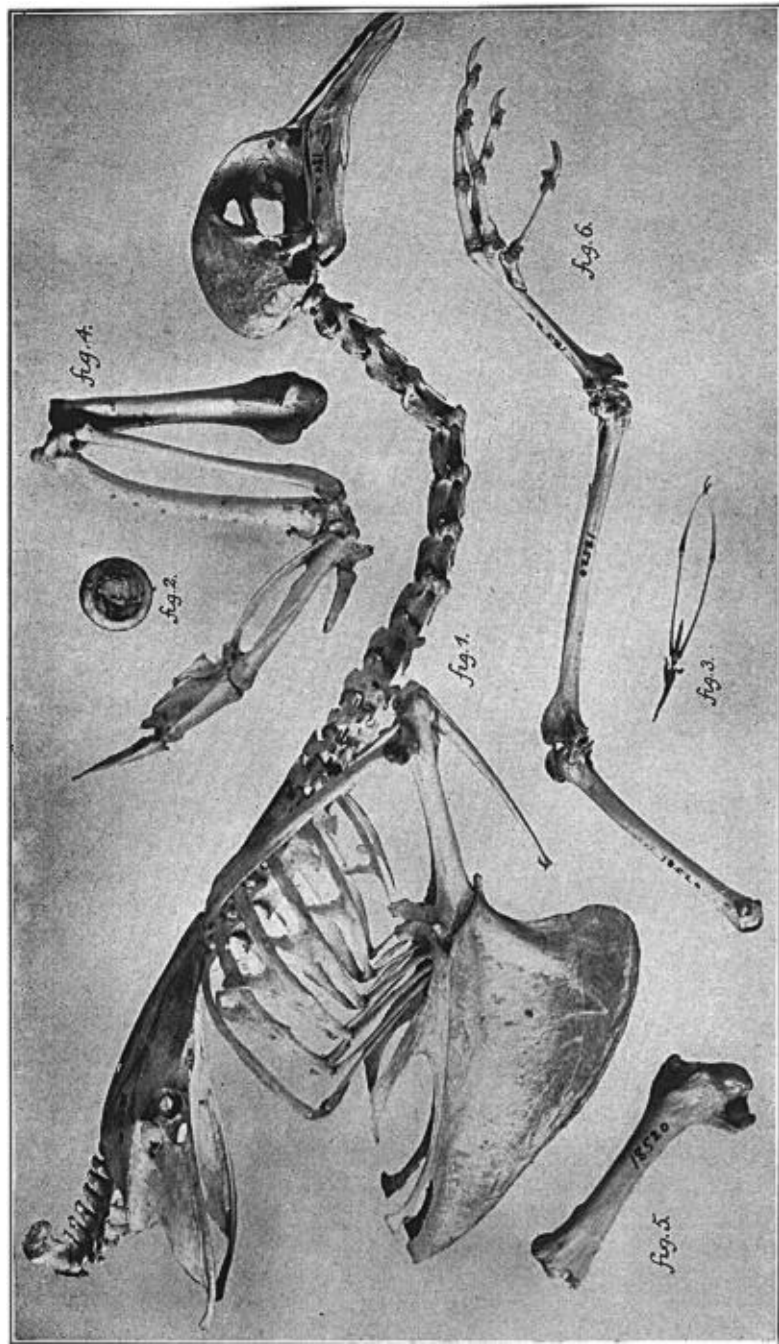
Plate XXXIV.

As far as I have been able to ascertain, there appears to be but one living specimen of *Ectopistes migratorius* in North America, and that one is a captive at the Zoölogical Garden of Cincinnati, Ohio, where, at the present writing, Mr. Stephan writes me it is doing well. When it dies, the species will be utterly extinct in this country, where formerly it existed in enormous flocks, often numbering many millions. Personally, I have witnessed but one flight of this pigeon, and that was early in the 70's at New Canaan, Connecticut, the second day of which I shot about fifty birds.

There has been no complete account published of the osteology of this bird, and certainly no good figures of its skeleton, though I

¹ Stuart, James. *Three Years in North America.* Edinburgh, 1833, Vol. II, p. 214.

² Thompson, Zadock. *History of Vermont. Natural, Civil and Statistical.* Burlington, p. 101.



OSTEOLOGY OF THE PASSENGER PIGEON, *Ectopistes migratorius*.

referred, in two or three of my earlier papers, to some of the characters of the latter in connection with the osteology of the American *Columbae* generally.¹ It is highly important that such an account should be published with a plate presenting all the essential characters of the skeleton. This will be useful at the present time, not only for comparison with the osteology of existing species, but also to the palæornithologist, in the event of the discovery of the bones of this bird in the ages to come.

I am indebted to the U. S. National Museum for the loan of a complete skeleton of this species, the only one in the collection, and the only one of which I have any knowledge (No. 18520, ad., Laurel, Md., ♂. ?). In connection with this loan, and for the prompt transmittal of the material, I have pleasure in thanking Dr. Charles W. Richmond, Assistant Curator of the Division of Birds, and his aid, Mr. J. H. Riley.

The plate illustrating the present article is a reproduction of the photograph I made direct of the aforesaid skeleton; it presents the bones natural size and conveniently arranged for study and comparative measurements.

There is nothing peculiar in the skeleton of this species — indeed, it is about as typically a columbidine one as we would meet with anywhere; a glance at the plate will be sufficient to convince the avian osteologist of this fact.

The Skull: — As in all true pigeons and in many fowls, the entire area of the superior part of the skull is smooth, being more or less flat transversely in the frontal region, and uniformly convex from before, backwards, from the vertex of the cranium. Superiorly,

¹ Shufeldt, R. W. "Notes on the Classification of the Pigeons." Amer. Nat., Feb. 1891, Vol. XXV, No. 290, pp. 157, 158.

—— "On the Comparative Osteology of the United States *Columbidae*." P. Z. S., Lond., Mar. 3, 1891, pp. 194–196.

—— "On the Osteology of the Pigeons (*Columbae*)." Jour. Morph., Vol. XVIII, No. 3, Bost., 1901, pp. 487–512. Pls. A, B. This paper is illustrated by four outline sketches, only one of which is devoted to *Ectopistes*, namely the pectoral aspect of the sternum.

—— "On Fossil Bird-Bones Obtained by Expeditions of the University of Pennsylvania from the Bone Caves of Tennessee." Amer. Nat., July 1897, pp. 645–650. On page 649 it is stated that 'The Passenger Pigeon is represented in the collection by subfossil bones from several adult individuals.' It is shown that some twelve or more specimens were found, and that the several bones differ in no way when compared with the corresponding ones of *Ectopistes* as the species existed in our avifauna years ago.

the margins of the large orbits are cultrate, while the posterior processes at lateral aspect of the brain-case, as the post-frontal and squamosal, are much reduced. *Basis cranii* is horizontally disposed, and the brain-case is of good capacity, while the rather high *foramen magnum* is of cordate outline, with the very small occipital condyle minutely notched posteriorly.

Large vacuities occur in the *interorbital septum*, as shown in Fig. 1 of the Plate, where, too, we are to observe the bulky *pars plana*, and the elongate, narrow, though capacious, external narial aperture.

The *superior mandible* is nearly straight, being gently decurved at its apex, and, as a whole, making an open angle with the slender, straight, zygomatic or infraorbital bar. A *lacrymal*, which is of good size, completely fuses with the *pars plana* in the adult.

A *vomer* appears to be absent, while the quadrates, the small pterygoids and the palatine structures are all as we find them in this group of birds generally — that is, in the typical and smaller varieties of the wild pigeons.

The *mandible* is of an acute V-shaped pattern and slender in its proportions, with a weak and short symphysis.

As to the *hyoidean arches*, they are as we find them in most pigeons, and not unlike those structures in certain of the smaller species of the tetraonine types, being slender and formed as shown in Fig. 3 of the Plate. As usual, the *glosso-hyal* is performed entirely in cartilage.

In Figure 2 the united *sclerotal plates* of an eye are shown; there are some 13 or 14 in either circlet, and they are shaped as we find them in other *Columbæ*.

The Trunk Skeleton: — Between the skull and the pelvis *Ectopistes* has eighteen vertebræ, while fourteen unite most solidly together to form the pelvic sacrum; finally, there are six in the caudal division of the vertebral column, and all beyond these last go to form the large, subtriangular *pygostyle*.

As in many fowls, the three leading dorsal vertebræ fuse to form one bone, and the *ribs* they support are connected with the sternum by costal ribs or hæmapophyses. This is also the case with the pair of ribs belonging to the last dorsal vertebra, the remaining ones being disposed as shown in Fig. 1 of the Plate.

Broad and somewhat shallow, the *pelvis* of the Passenger Pigeon is, nevertheless, capacious, and reminds one of this bone in some of the *Tetraonidæ*. Its sacral roof is a broad, lozenge-shaped one, in close contact with the ilium upon either side; but coössification does not take place at any point along the sutural line.

As we might expect in a bird of such powerful flight, the keel or carina of the *sternum* is very extensive, with its fore-part thick and strong. There is a pair of xiphoidal processes on either side, posteriorly, each having an expanded distal end as shown in Figure 1 of the Plate. Four *costal ribs* articulate with either costal border, and a minute manubrium is seen to project in front.

Powerful flight in this bird also accounts for the presence in its skeleton of a *scapular arch*, with its usual component bones large and strong. *Os furculum* is of a broad, U-shaped form with a minute hypocleidium below. Either *scapula* is enlarged posteriorly, the distal extremity being truncate from within, outwards. A *coracoid* is an unusually large, long bone for a bird of the size of this pigeon, and it is very strong and straight. The *os furculum* does not meet the scapula, on either side, in articulation, and the free ends of this arch are but slightly expanded.

The Limbs: — As we would naturally expect, the skeleton of the pectoral limb indicates great power of flight. The several bones, though short, are massive, and in close and extensive contact at their articulations.

The *humerus* is short and straight and the shaft correspondingly stout. Its radial crest is triangular in outline as shown in Fig. 5.

Radius of the antibrachium is also straight, while the massive *ulna* exhibits more or less curvature along its entire continuity (Fig. 4).

In extreme length the humerus measures 4.3 cms.; the ulna 7.55 cms., and the radius, as in the case of the humerus, 4.3 cms. All of these bones, which is also the case in the pelvic limb, do not quite come up to these measurements, owing to there having been a slight obliquity in the point of view as they were placed to be photographed. This could not be avoided, as the bones of the limbs are *articulated*, and I had no right to separate them. The *carpo-metacarpus* has an extreme length of 2.9 cms., as in the Plate. Comparatively speaking, the bones in the thigh, leg and tarsus are

long and more or less slender; their principal characters are seen in Fig. 6 of the Plate. The *fibula* is free, and it extends but two-thirds down the side of the nearly straight shaft of the *tibio-tarsus*. The latter presents distally in front the little 'osseous bridge,' spanning obliquely the groove for the tendons which pass there in life. With respect to their extreme lengths, the femur measures 3.95 cms.; the *tibio-tarsus* 5.5 cms., and the *tarso-metatarsus* 3.0 cms.

In a former paper I have presented the affinities of *Ectopistes migratorius*, and this will obviate the necessity of my touching upon this side of the subject in the present connection, which pretends to be but a brief sketch of this fine representative of the *Columbae* which will shortly be extinct.

EXPLANATION OF PLATE.

(All figures natural size.)

Ectopistes migratorius. No. 18520. Collection U. S. National Museum.
From a photograph by the author.

FIG. 1. Skull and trunk skeleton; right lateral view, with bones all *in situ*.

FIG. 2. Circler of *sclerotal plates* of right eye, with the dried enclosing membranes of the globe attached behind.

FIG. 3. *Hyoid arches*, seen from below; the cornua are drawn together, and the glosso-hyal is in cartilage.

FIG. 4. Right pectoral limb, viewed upon its palmar aspect, with all the bones *in situ*.

FIG. 5. Left *humerus*, seen upon anconal aspect.

FIG. 6. Left *pelvic limb*, inner or mesial aspect, with all the bones *in situ*. The osseous *patella* is minute and a calcaneal sesamoid of some size is to be seen above the hypotarsus.